


STOÐKERFISVANDAMÁL1:

slitgigt, öldrun



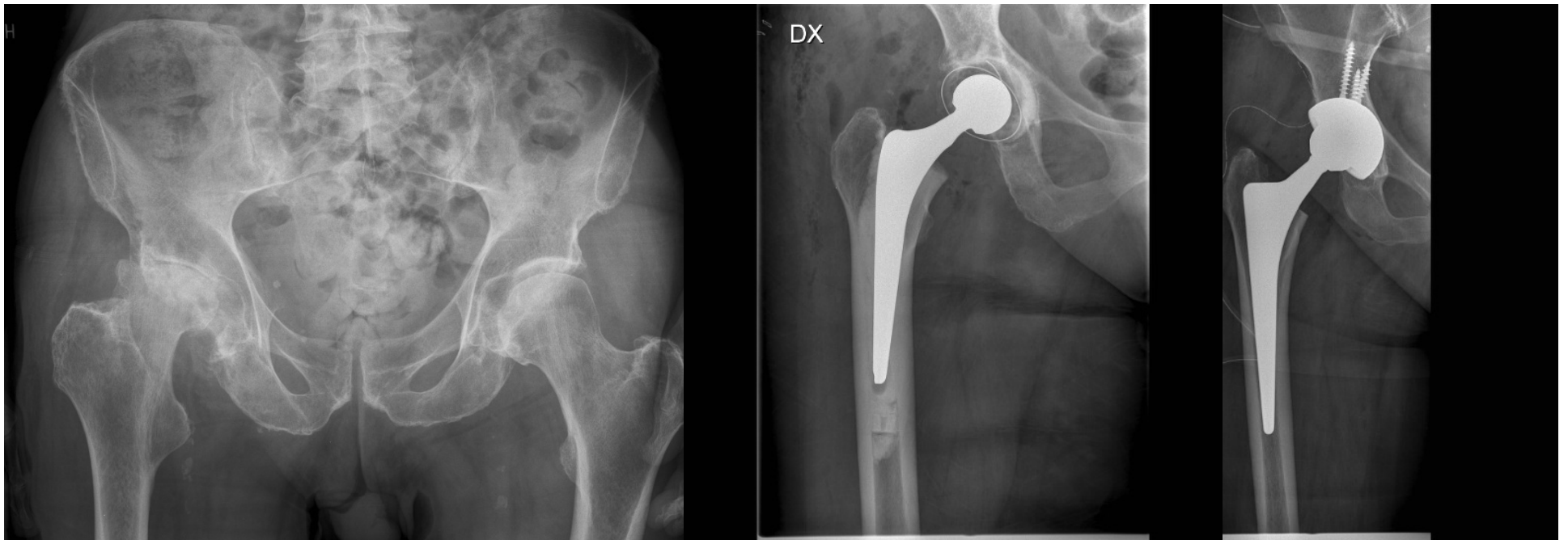
Halldór Jónsson jr

Helstu bæklunarvandamálin!

- Slitgigt í stórum liðum
- Öldrun
- Sýking í liðum og beinum
- Æxli og meinvörp



Slitgigt í stórum liðum: mjöðm

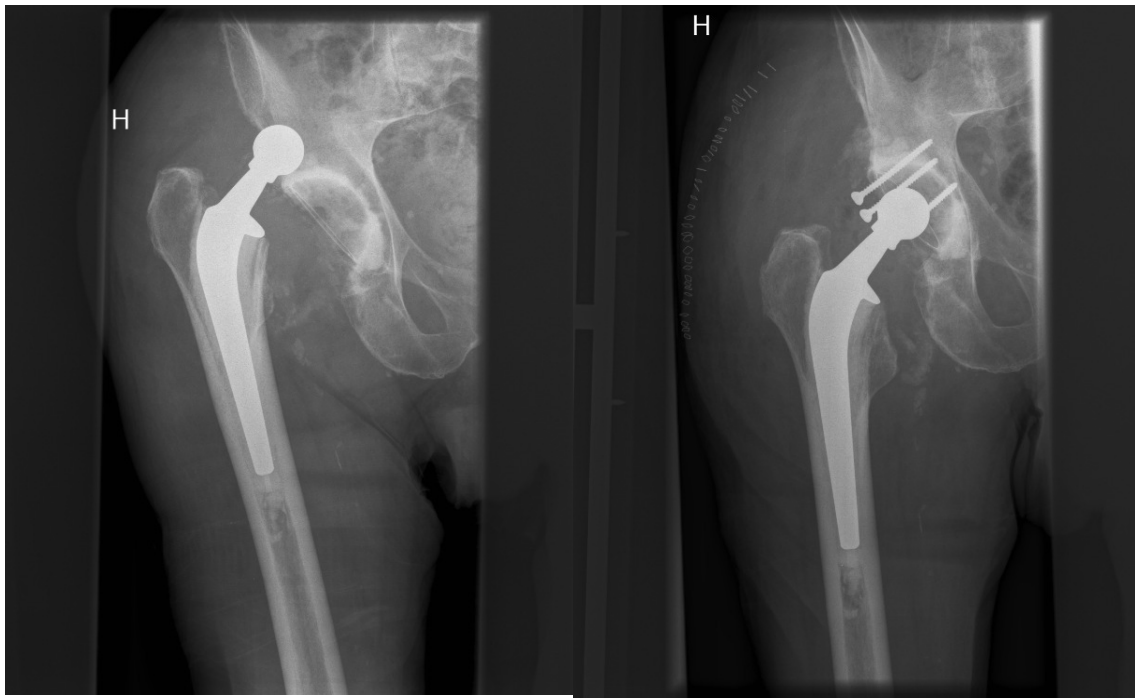


Frumslit (primary) eða
v/annarra orsaka (secondary)

Cement

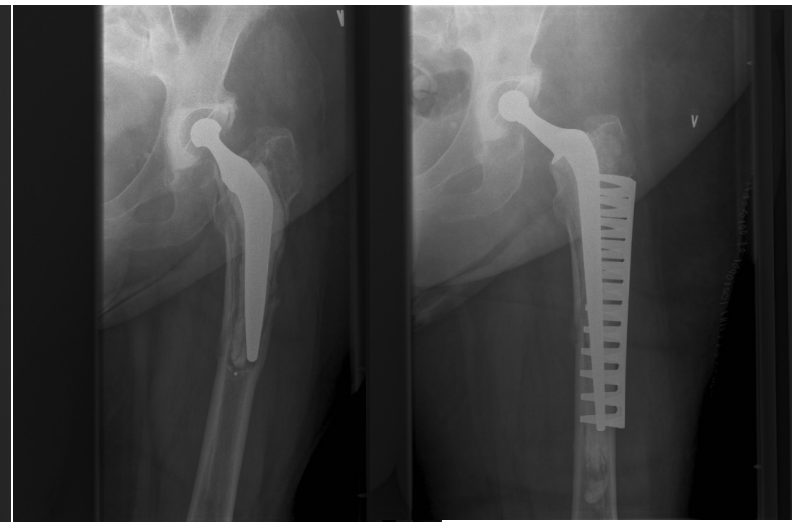Ekki cement

Slitgigt í stórum liðum: mjöðm



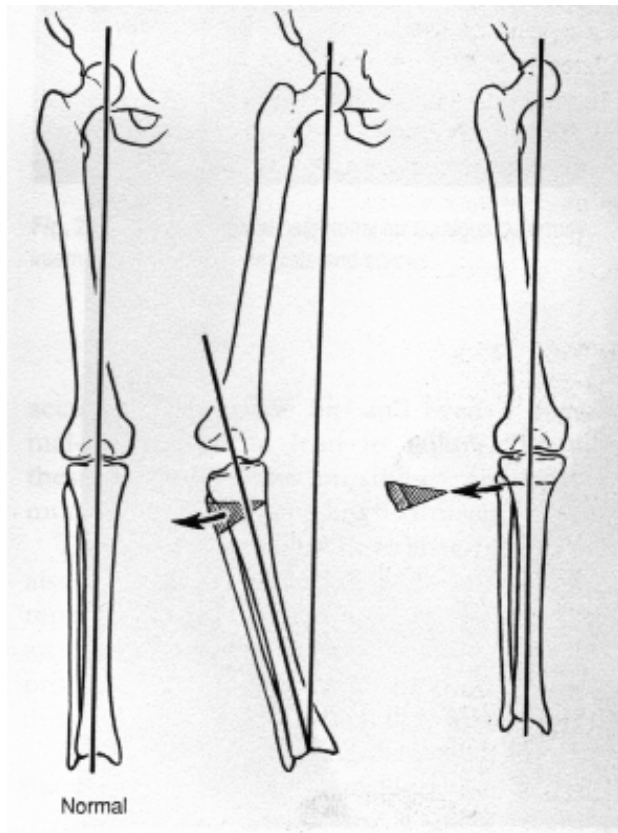
Liðhlaup

Skálarauki

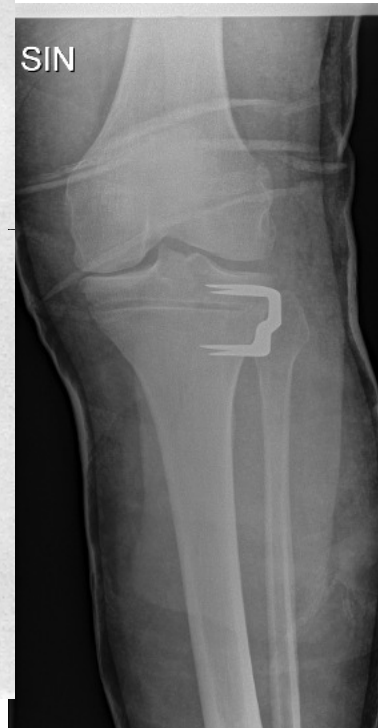

Periprosthetic
brot

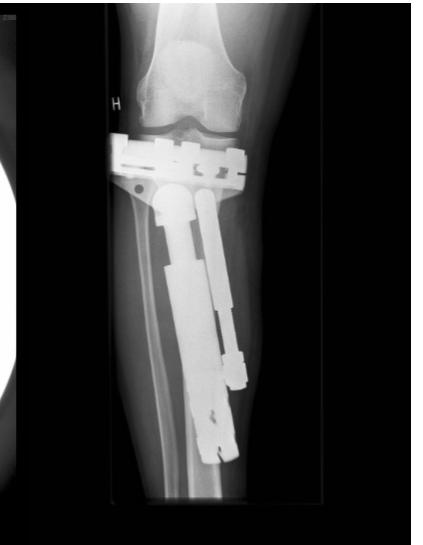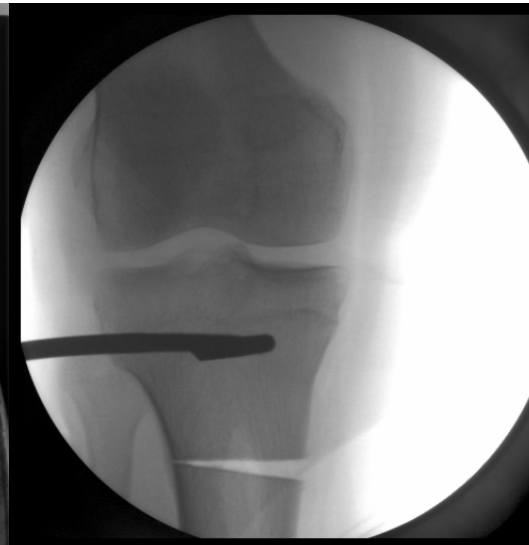Slitgigt í stórum liðum: hné



HKA vinkill

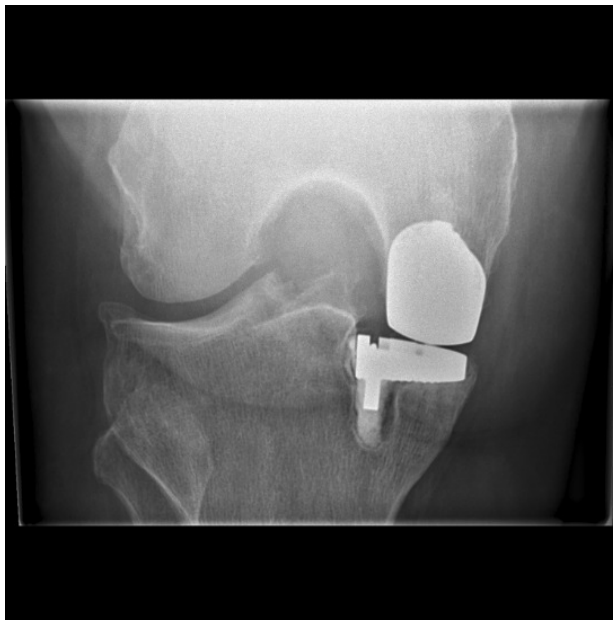


Mínus osteot

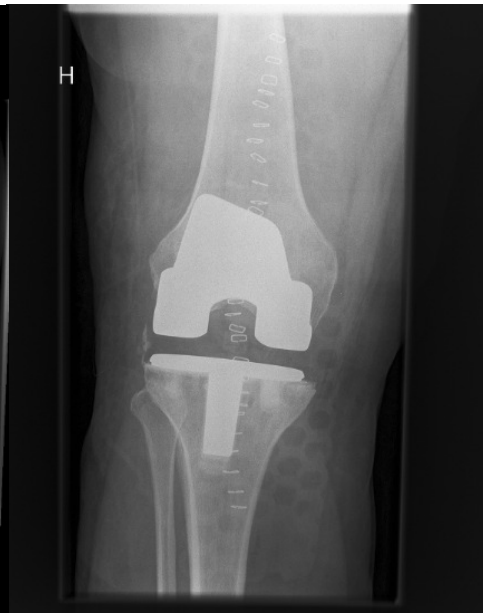

Plús osteotomía:
Ex fix eða bein + plata

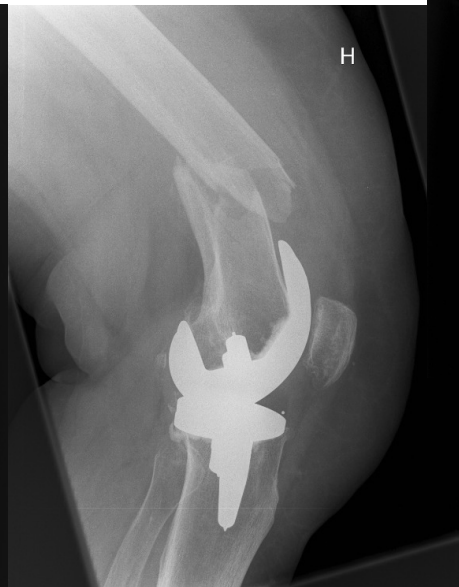Slitgigt í stórum liðum: hné



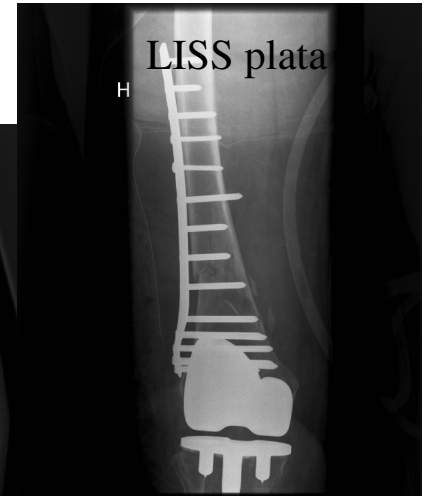
Hálfliður



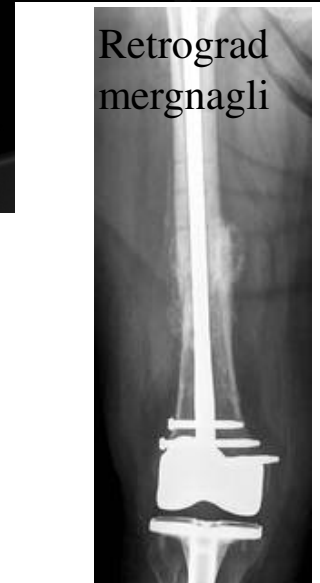Heilliður



Brot ofan hnéprótesu

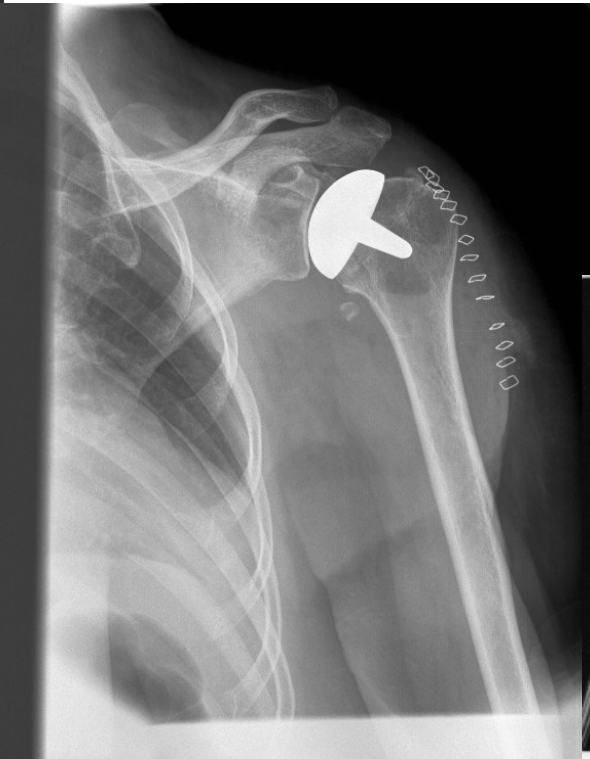
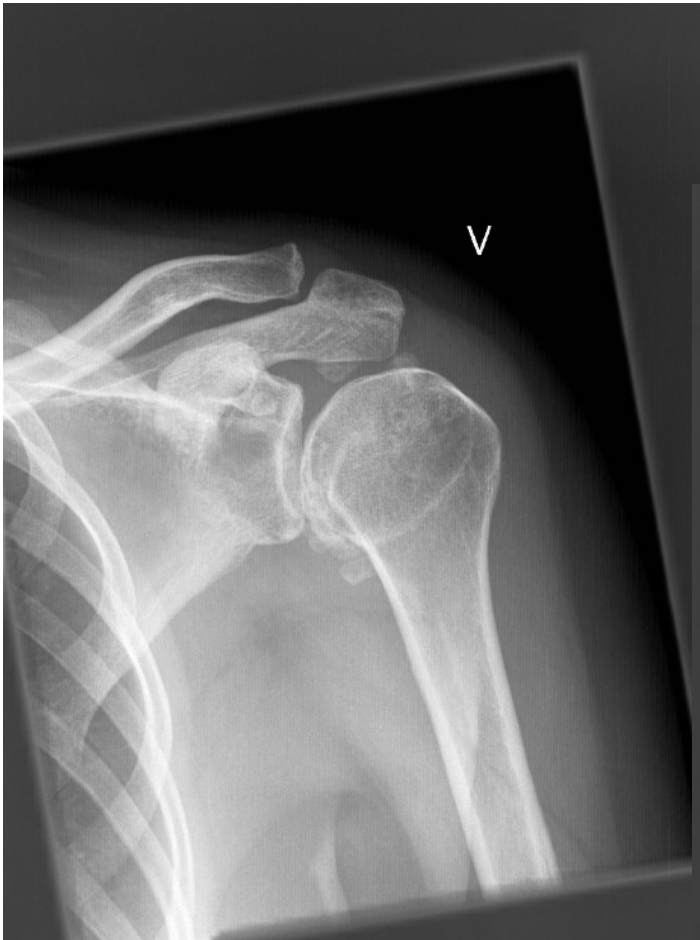
LISS plata

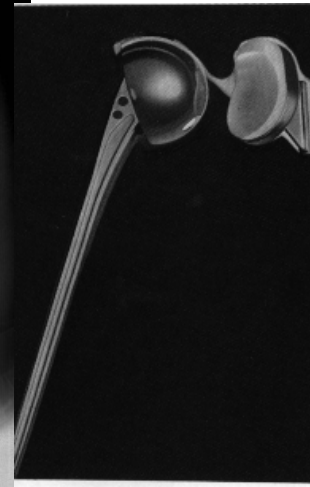


Retrograd
mergnagli

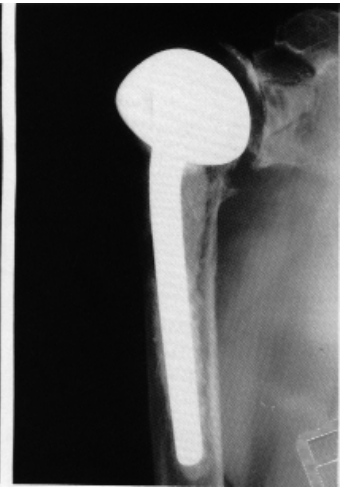Slitgigt í stórum liðum: öxl



Resurfacing



Mono-

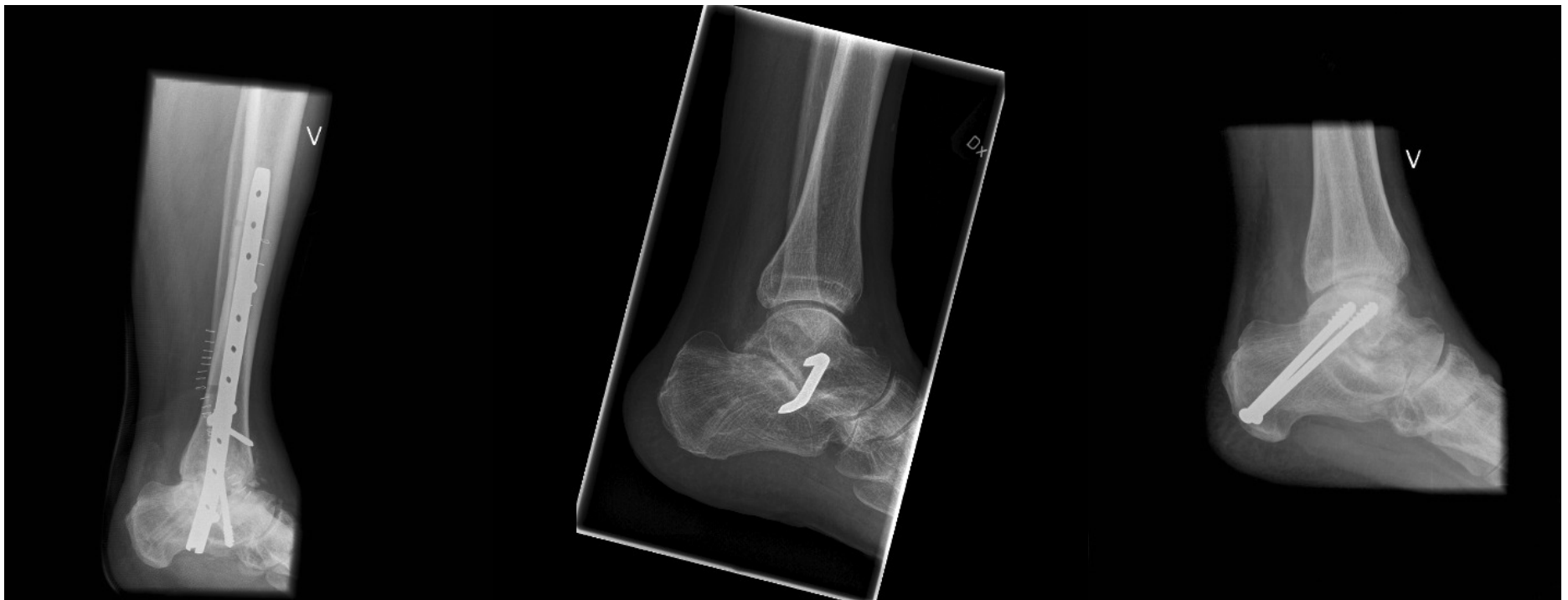

Bi-polar

Slitgigt í stórum liðum: ökkli

-talocrural

-subtalar



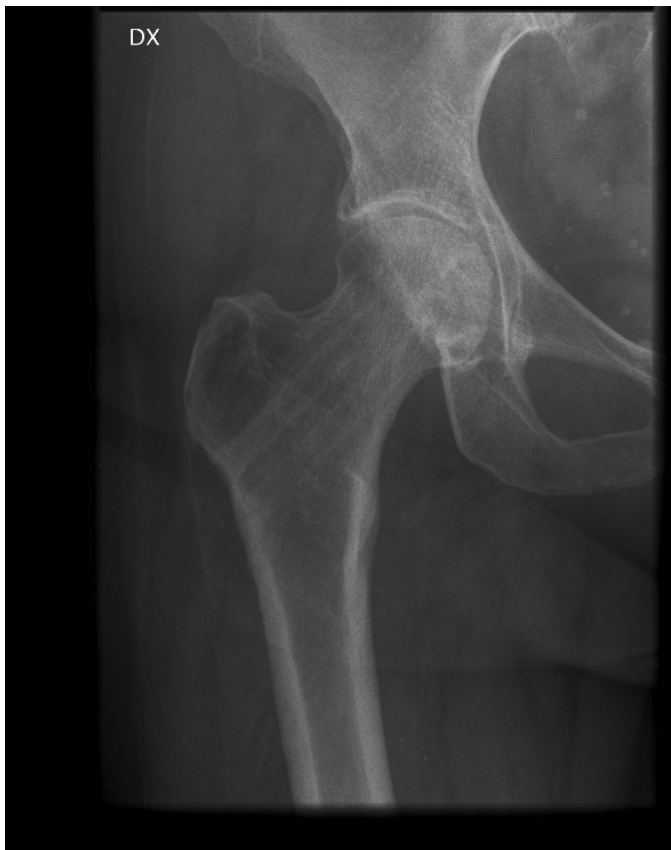Naglar

Zinklar

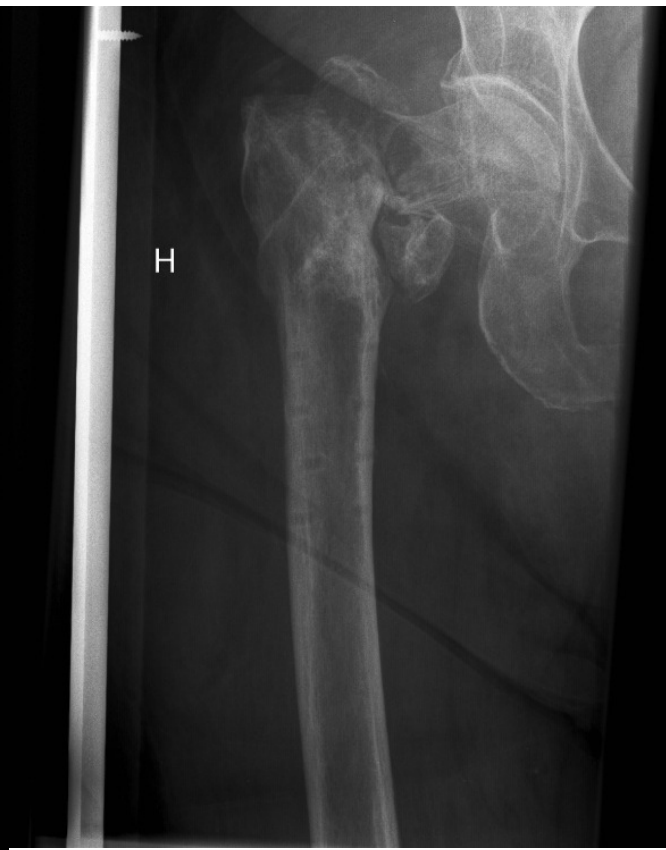Skrúfur

..... öldrun

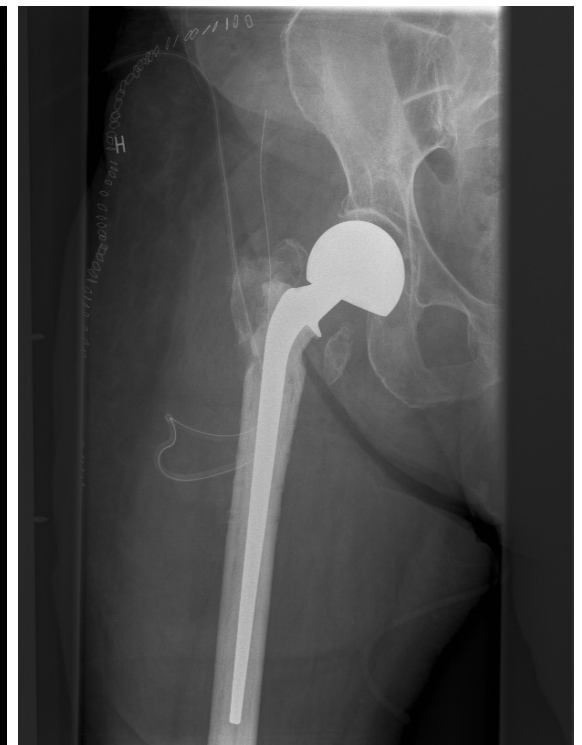Afleiðingar mjaðmabrota



Caput necrósá e. Collum fx



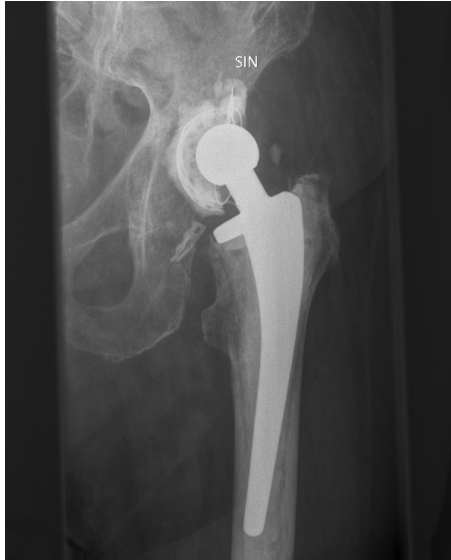Pseudarthrosa e. Trokanter fx



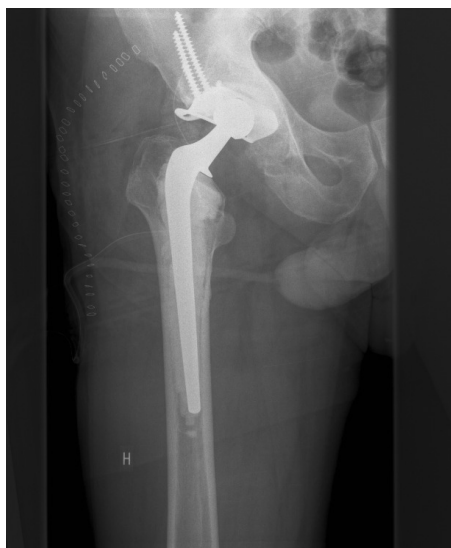Bi-polar gerviliður

..... öldrun

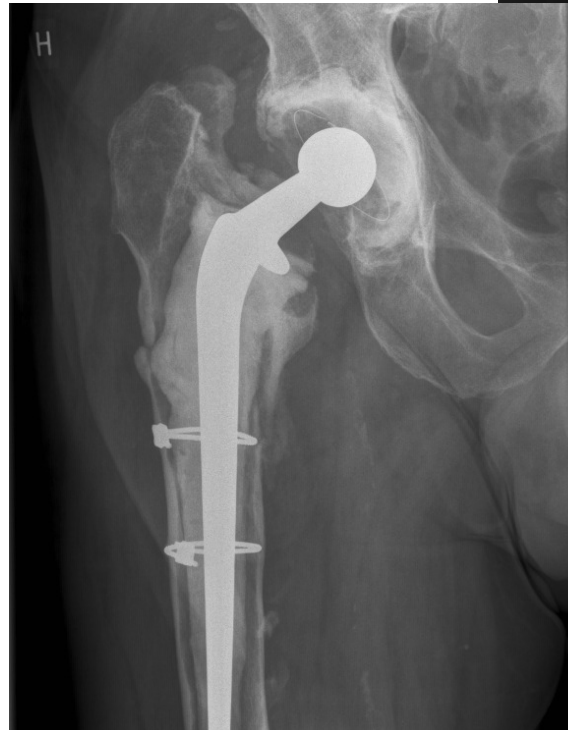Lausir gerviliðir (mjaðmir og
hné)



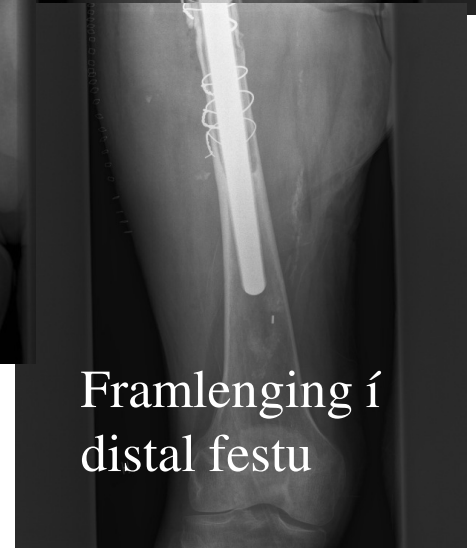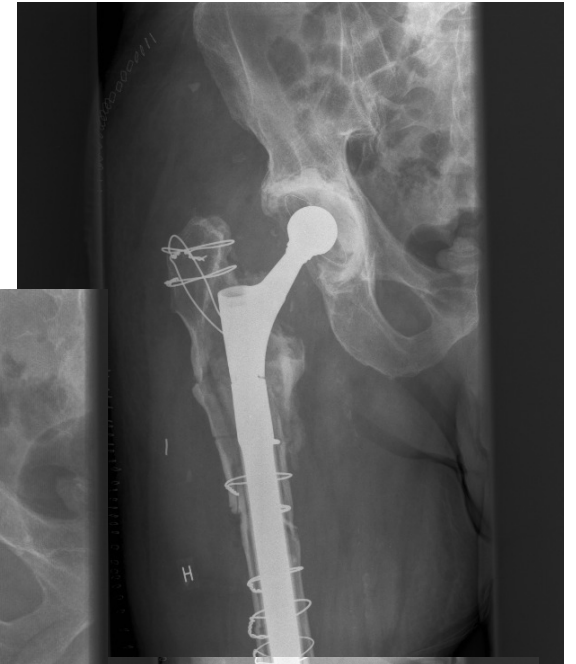Laus bolli



Acetabular
styrking

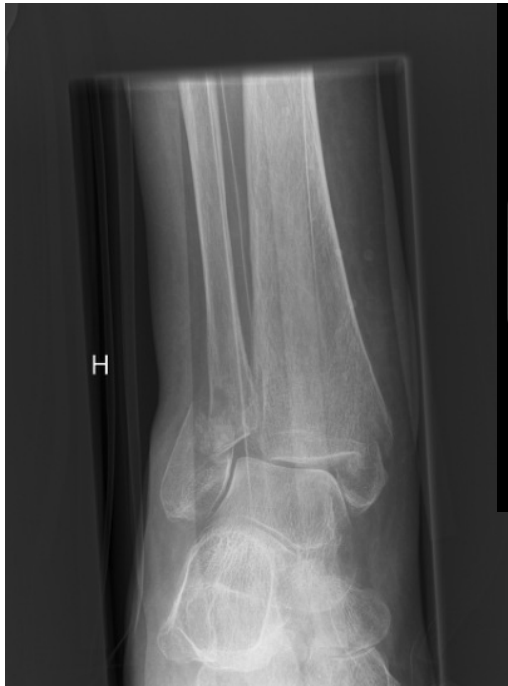

Laus stilkur

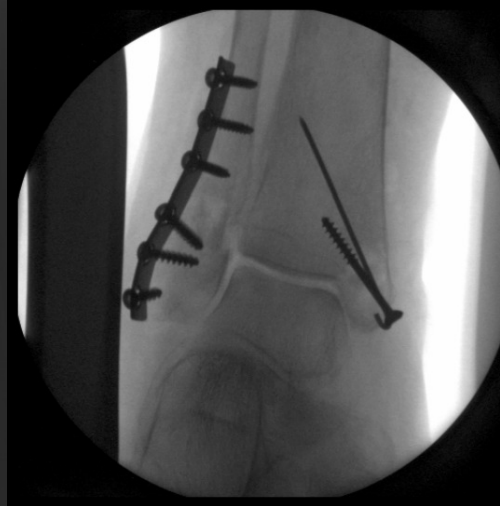

Framlenging í
distal festu

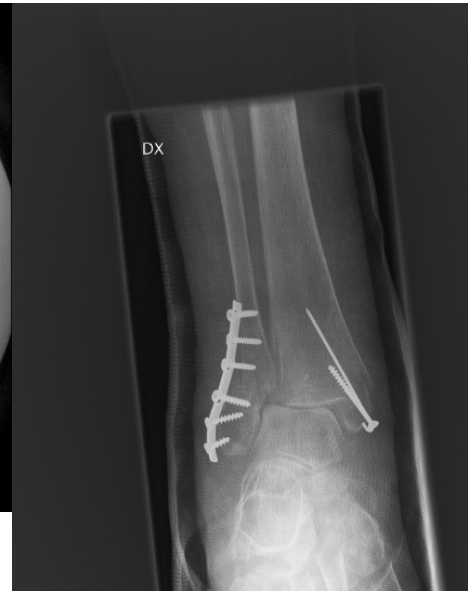..... öldrun



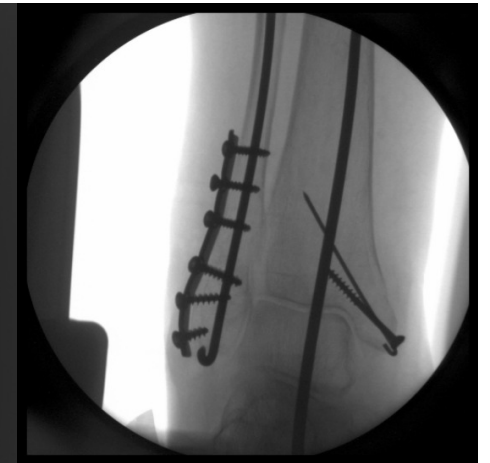“Osteoporotic”
ökklabrot



“Hefðbundin ORIF”

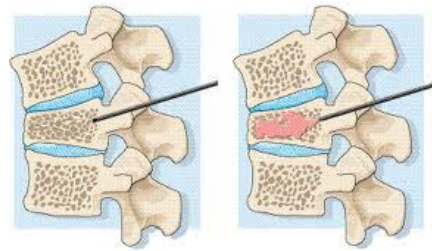
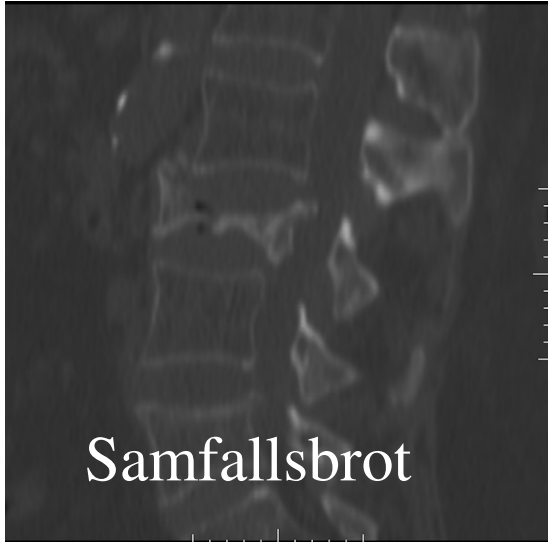

Festibúnaður
heldur ekki

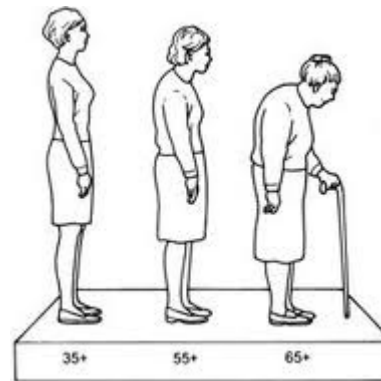
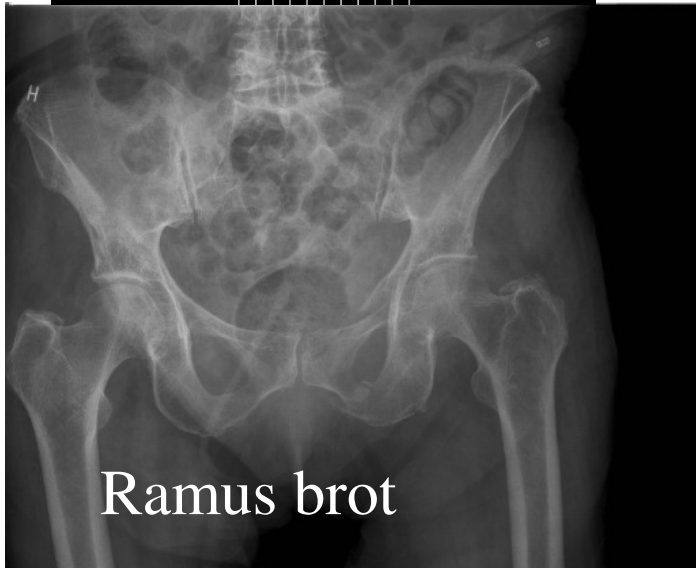

“First line of defence”

..... öldrun



Vertebroplasty





TAKK!
